European Journal of Heart Failure (2009) **11**, 945–951
doi:10.1093/eurjhf/hfp124

Left ventricular remodelling and torsional dynamics in dilated cardiomyopathy: reversed apical rotation as a marker of disease severity†

Bogdan A. Popescu[1,2]*, Carmen C. Beladan[1,2], Andreea Călin[1,2], Denisa Muraru[2], Dan Deleanu[2], Monica Roşca[1,2], and Carmen Ginghină[1,2]

[1]'Carol Davila' University of Medicine and Pharmacy, 'Prof. Dr C. C. Iliescu' Institute of Cardiovascular Diseases, Sos. Fundeni 258, sector 2, 022328 Bucharest, Romania; and [2]'Prof. Dr C. C. Iliescu' Institute of Cardiovascular Diseases, Bucharest, Romania

Received 18 June 2009; revised 29 July 2009; accepted 7 August 2009

Aims Decreased left ventricular (LV) rotation and torsion and even reversed systolic apical rotation have been described in patients with dilated cardiomyopathy (DCM). We sought to test in patients with DCM whether reversed apical rotation with loss of LV torsion is related to the extent of LV remodelling and to the severity of LV dysfunction.

Methods and results Fifty consecutive patients with DCM (aged 49 ± 13 years) were enrolled prospectively. Forty-seven healthy volunteers served as controls. All subjects underwent clinical examination, 12-lead electrocardiography, and a comprehensive echocardiogram. Basal and apical LV rotation and LV torsion were quantified by speckle tracking echocardiography. Left ventricular systolic rotation and torsion were reduced in patients, compared with controls ($P < 0.001$). Normally directed (counterclockwise) apical rotation was found in 24 patients (group 1), whereas 26 had reversed (clockwise) apical rotation (group 2). Patients in group 2 had larger LV volume, increased LV sphericity ($P \leq 0.02$), more severe systolic dysfunction (ejection fraction 26 ± 7 vs. 33 ± 12%), and higher filling pressures (E/E′ ratio 19 ± 10 vs. 14 ± 6; $P < 0.05$). The main correlates of LV apical rotation were LV volume, sphericity index, and QRS duration.

Conclusion Reversed apical rotation and loss of LV torsion in patients with DCM is associated with significant LV remodelling, increased electrical dyssynchrony, reduced systolic function, and increased filling pressures, indicating a more advanced disease stage.

Keywords Dilated cardiomyopathy • Left ventricular remodelling • Apical rotation • Left ventricular torsion • Speckle tracking echocardiography

Introduction

Left ventricular (LV) torsional deformation is generated by the contraction of the left ventricle's helically oriented myofibres. When viewed from the apex, systolic rotation of the base is clockwise, while apex rotation is counterclockwise. Left ventricular torsion allows a uniform distribution of fibre stress and fibre shortening across the wall, representing a critically important mechanism for both ejection and filling.[1–3] Systolic apical rotation is the main determinant of LV systolic torsion, while rapid diastolic apical back rotation causes a fast decline of LV pressure, playing an important role in the suction of blood into the LV, promoting its filling at low pressures.[4,5] Therefore, a normally functioning LV apex is very important for normal cardiac performance. Speckle tracking echocardiography (STE) has recently been proposed and validated as a feasible method for measuring LV rotation and torsion.[6,7]

We have recently observed a group of patients with dilated cardiomyopathy (DCM) in whom systolic apical rotation, assessed by STE, was reversed (i.e. clockwise). These patients had severe LV

* Corresponding author. Tel: +40 21 3175227, Fax: +40 21 3175227, Email: bogdan.a.popescu@gmail.com

† This study was presented in part (as an oral abstract) at the Heart Failure Congress 2009, Nice, 30 May–2 June.

remodelling (in terms of size and shape) and severe systolic and diastolic dysfunction. We speculated that reversed apical rotation with consequent loss of LV torsion is due to severe dilation and increased sphericity of the LV associated with significant changes in myofibre orientation. In turn, loss of LV torsion leads to further decline in LV function, perpetuating a vicious circle. The purpose of this study was, therefore, to address the following hypotheses in patients with DCM: (i) reversed apical rotation is related to severe LV structural remodelling; and (ii) reversed apical rotation is associated with more severe LV dysfunction.

Methods

We studied 88 consecutive patients with DCM who had been referred to our echocardiography laboratory for LV function assessment. The diagnosis of DCM was established by: (i) the presence of LV dilation (LV systolic volume indexed to body surface area >30 mL/m^2); (ii) LV ejection fraction (LVEF) $<50\%$; (iii) absence of coronary artery disease on history, echocardiography, and/or coronary angiography; (iv) absence of primary valvular heart disease; (v) absence of cardiac muscle disease secondary to neuromuscular diseases or any known systemic condition; and (vi) absence of echocardiographic criteria for infiltrative heart disease, LV non-compaction, or hypertrophic cardiomyopathy. After the exclusion of patients with a poor acoustic window or who were technically unsuitable for speckle tracking analysis (10 patients), non-sinus rhythm (23 patients), and cardiac pacemaker (5 patients), the remaining 50 patients with DCM were analysed. Coronary angiography was performed in 30 of these 50 patients before echocardiography, for routine clinical purposes, at the discretion of the referring physician. Forty-seven age-matched healthy volunteers served as the control group. They had no evidence of heart disease by physical examination, electrocardiography (ECG), or echocardiography, and were taking no medication.

All subjects underwent clinical examination, 12-lead ECG, and a comprehensive echocardiogram. All patients were on appropriate medical therapy including beta-blockers, ACE inhibitors, and diuretics. The investigation conforms with the principles outlined in the Declaration of Helsinki. All subjects gave their informed consent to participate in the study, the protocol of which was approved by the local Ethics Committee.

Echocardiography

All subjects underwent two-dimensional conventional Doppler echocardiography and STE. Images were obtained using a cardiac ultrasound machine (Vivid 7 Dimension; GE Healthcare, Milwaukee, WI, USA) equipped with a 4S probe. Greyscale images were obtained using second-harmonic imaging. Endocardial LV fractional shortening (LVFS) was calculated according to the American Society of Echocardiography/European Association of Echocardiography recommendations.[8] Left ventricular volumes and LVEF were measured using the modified Simpson's rule from apical six-chamber views and were normalized to body surface area. Left ventricular mass was calculated by the equation of Devereux *et al.*[9] The overall LV chamber shape was evaluated using the sphericity index, calculated as the ratio between the long and minor axis dimensions, obtained at end-diastole from the apical four-chamber view.

Peak systolic (S) and peak early diastolic mitral annular velocities (E′) were obtained by pulse wave tissue Doppler imaging from the apical four-chamber view using the septal site. The ratio of peak early diastolic transmitral flow velocity E to septal E′ was used to assess LV filling pressure.[10] Mitral regurgitation was assessed qualitatively by Doppler echocardiography (mild, moderate, and severe).[11]

Greyscale digital cine loops triggered to QRS complexes were acquired from two LV short-axis planes at the basal and apical levels for rotation and torsion analysis. Care was taken to ensure that the basal short-axis plane contained the mitral valve. The apical plane was acquired distally to the papillary muscles and transducer position was optimized to ensure a proper, circular short-axis cut, as previously described.[12] In each plane, three consecutive cardiac cycles were acquired during breath-hold at a frame rate of 60–100 frames/s, without using dual focus, and stored on hard disk for off-line analysis using commercially available software (EchoPAC PC 8.0; GE Healthcare). Off-line analysis was performed by a single observer blinded to clinical data.

The region of interest of the LV was from the endocardial margin to the epicardial margin, thus delineating the entire circumference. The width of the region of interest was adjusted as needed to fit the wall thickness, as previously described.[7] The tracking quality of each segment was indicated by the software, and segments with insufficient tracking quality were excluded. This method has already been validated against tagging MRI for measuring LV torsion.[7]

Averaged apical and basal rotation data were used to calculate LV twist and torsion. Left ventricular twist was calculated as the net difference in LV rotation at isochronal time points between the apical and basal short-axis planes. The short-axis views at the apical and basal levels were recorded immediately one after another in order to select cardiac cycles with identical or very similar heart rates for the measurement of apical and basal rotation. Mean heart rate was 69.1 ± 10.4 bpm for recordings at the basal level and 68.9 ± 10.6 bpm at the apical level. Moreover, the software used did not allow calculation of LV twist by this method if there was a significant difference in heart rate between cycles used to measure apical and basal rotation.

Left ventricular torsion was defined as LV twist divided by LV diastolic longitudinal length measured in the four-chamber view. Particular attention was paid to the direction of systolic apical rotation: normal (counterclockwise) or reversed (clockwise), which was documented for each patient. The following measurements were performed: peak basal and peak apical rotation, peak LV twist, peak LV torsion (*Figure 1*).

Statistical analysis

Measurements are presented as mean $\pm$ SD. Variables were compared using Student's *t*-test, analysis of variance, or the χ^2 test as appropriate. Relationships between different parameters were assessed by correlation analysis (the Pearson's method). Measurement variability was assessed for peak apical and peak basal rotation in a randomly selected group of 15 patients with DCM. For inter-observer variability, measurements were carried out by a second operator on previously acquired images, but not necessarily the same heart beats. For intra-observer variability, two sets of measurements were carried out by the same operator, 1 month apart. Variability was calculated as the absolute difference between two measurements divided by the mean of the two measurements. All statistical analyses were performed using SPSS 14.0 software for Windows (SPSS, Chicago, IL, USA). A two-sided *P*-value of 0.05 was considered significant.

Results

Clinical characteristics of the study group are presented in *Table 1*. No significant differences were noted in age, heart rate, and body

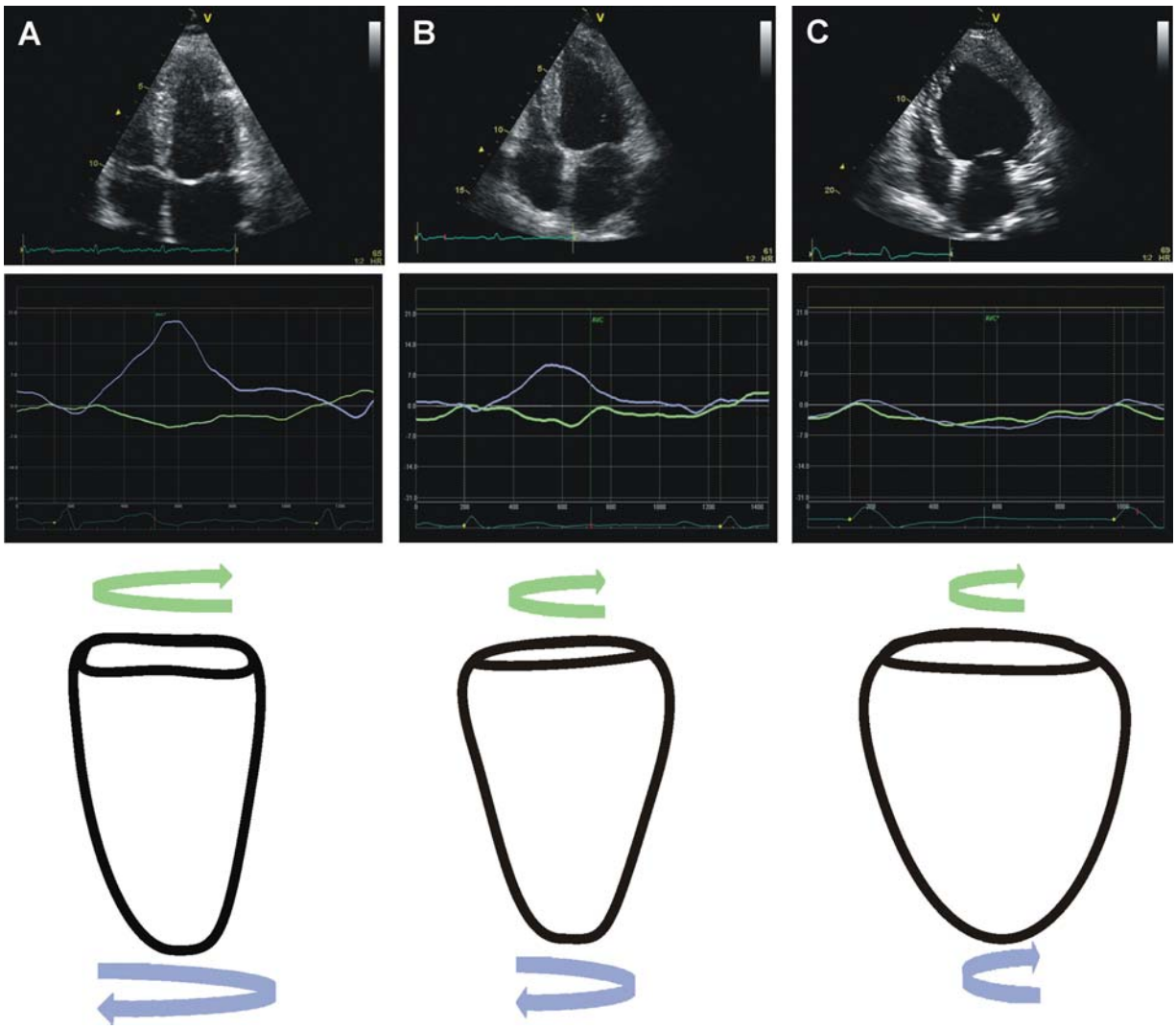

Figure 1 Two-dimensional apical four-chamber views (top), speckle-tracking left ventricular (LV) rotation curves (middle), and schematic representations of LV geometry and rotation (bottom) in a normal subject (*A*); a DCM (+) patient (*B*); and a DCM (−) patient (*C*). Top row: progressive increase in LV dimensions and sphericity, from normal (A) to DCM with severe LV remodelling (C). Middle row: (A) normal LV apical (blue) and basal (green) rotation curves; (B) normally directed, but reduced in amplitude LV rotation curves; (C) reversed apical rotation with clockwise (−) motion of both apex and base in the patient with severely dilated LV. Bottom row: changes in LV geometry and LV rotation at basal (green arrow) and apical (blue arrow) levels from normal (A) to mildly dilated (B), and severely dilated LV (C). The amplitude of both basal and apical rotation is reduced but normally directed in the patient with DCM and mildly dilated LV (B). Reversed apical rotation is seen in association with severe LV remodelling (C).

surface area between patients with DCM and control subjects. Distribution of New York Heart Association (NYHA) class among patients with DCM was as follows: 17 patients were in class II, 23 in class III, and 10 in class IV. Coronary arteries were normal in all the patients who underwent coronary angiography. The mean frame rate of data sets obtained from greyscale images was 76 ± 8 in patients and 84 ± 14 in controls.

Patients with DCM had significantly larger LV dimensions (diameter, volume, and mass), sphericity indices, and E/E′ ratios. As expected, LVFS, LVEF, and systolic and diastolic mitral annular velocities were significantly lower in patients than in control subjects (*Table 2*).

In patients with DCM, LV rotation was reduced at both apical (0.1 ± 5.5 vs. 15.8 ± 6.3°, $P < 0.001$) and basal (−2.8 ± 3.1 vs. −6.0 ± 2.8°, $P < 0.001$) levels compared with control subjects.

A reversed systolic LV apical rotation was observed in a subgroup of patients with DCM. We divided patients with DCM in two subgroups, accordingly: 24 patients had normally directed (counterclockwise) apical rotation, DCM (+), and 26 patients had reversed (clockwise) apical rotation, DCM (−). There were no significant differences between these two subgroups in terms of age, body surface area, heart rate, blood pressure, or medication. The NYHA class was higher in patients with reversed apical rotation, but the difference did not reach statistical significance.

Table 1 Clinical characteristics

	Controls (n = 47)	DCM (n = 50)	P-value
Men, n (%)	16 (34)	41 (82)	<0.001
Age (years)	45 ± 13	49 ± 13	0.08
Heart rate (bpm)	69 ± 10	73 ± 13	0.09
Body surface area (kg/m^2)	1.80 ± 0.17	1.86 ± 0.17	0.14
Systolic blood pressure (mmHg)	114 ± 8	110 ± 15	0.10
Diastolic blood pressure (mmHg)	69 ± 4	68 ± 9	0.26
QRS duration (ms)	85 ± 5	132 ± 37	<0.001

Table 2 Echocardiographic variables in control subjects and patients with dilated cardiomyopathy

	Controls (n = 47)	DCM (n = 50)	P-value
LVEDD (mm/m^2)	27 ± 2	40 ± 7	<0.001
LVESD (mm/m^2)	16 ± 2	34 ± 8	<0.001
LVEDV (mL/m^2)	51 ± 8	128 ± 60	<0.001
LVESV (mL/m^2)	19 ± 4	93 ± 49	<0.001
LV sphericity index	1.90 ± 0.2	1.57 ± 0.2	<0.001
LV mass (g/m^2)	86 ± 12	194 ± 65	<0.001
LVFS (%)	40 ± 5	16 ± 6	<0.001
LVEF (%)	61 ± 3	29 ± 11	<0.001
Peak S (cm/s)	7.5 ± 1.1	4.2 ± 1.5	<0.001
Peak E′ (cm/s)	10.0 ± 2.2	5.0 ± 1.9	<0.001
E/E′ ratio	8 ± 2	17 ± 9	<0.001

LVEDD, left ventricular end-diastolic diameter; LVESD, left ventricular end-systolic diameter; LVEDV, left ventricular end-diastolic volume; LVESV, left ventricular end-systolic volume; LVFS, left ventricular fractional shortening; LVEF, left ventricular ejection fraction.

Larger LV dimensions (diameters, volumes, and mass) and increased sphericity were found in DCM (−) patients (*Table 3*). These patients also had significantly lower values for echocardiographic parameters of LV systolic function (LVFS and LVEF) and increased LV filling pressures (higher E/E′ ratios). Degree of mitral regurgitation and QRS duration were significantly higher in the DCM (−) group (*Table 3*).

In the DCM (+) group, peak basal rotation was $-2.5 \pm 3.4^\circ$ and peak apical rotation was $5.1 \pm 2.8^\circ$. Left ventricular torsion was lower in DCM (+) patients than in control subjects: 0.7 ± 0.4 vs. $2.6 \pm 0.8^\circ$ per cm, $P < 0.001$. Five patients in the DCM (+) group had reversed basal rotation.

In the DCM (−) group, peak basal rotation was $-3.0 \pm 2.9^\circ$ and peak apical rotation was $-4.4 \pm 2.9^\circ$. Therefore, LV torsion was basically lost in this group, with a calculated mean value of $-0.1 \pm 0.4^\circ$ per cm, significantly lower than in the DCM (+) group and than in normals ($P < 0.001$ for both). There were four patients in the DCM (−) group having reversed basal rotation.

Table 3 Clinical and echocardiographic variables in the two groups of patients with dilated cardiomyopathy

	DCM (+) (n = 24)	DCM (−) (n = 26)	P-value
Men, n (%)	18 (75)	23 (88)	0.2
Age (years)	51 ± 13	48 ± 13	0.4
Body surface area (Kg/m^2)	1.85 ± 0.19	1.86 ± 0.15	0.7
Heart rate (bpm)	75 ± 13	72 ± 13	0.3
QRS duration (ms)	114 ± 33	147 ± 38	0.004
Mitral regurgitation degree (0–3)	1.3 ± 0.8	1.8 ± 0.8	0.03
LVEDD (mm/m^2)	37 ± 7	42 ± 7	0.02
LVESD (mm/m^2)	31 ± 7	36 ± 8	0.01
LVEDV (mL/m^2)	107 ± 44	148 ± 66	0.01
LVESV (mL/m^2)	75 ± 40	110 ± 51	0.01
LV sphericity index	1.64 ± 0.19	1.51 ± 0.20	0.02
LV mass (g/m^2)	173 ± 48	213 ± 72	0.02
LVFS (%)	18 ± 6	14 ± 5	0.01
LVEF (%)	33 ± 12	26 ± 7	0.02
Peak S (cm/s)	4.5 ± 1.5	3.9 ± 1.4	0.10
Peak E′ (cm/s)	5.6 ± 1.9	4.4 ± 1.7	0.04
E/E′ ratio	14 ± 6	19 ± 10	0.04

Abbreviations as in *Table 2*.

Apical rotation was significantly different between the two DCM groups ($P < 0.001$), whereas basal rotation was not different ($P = 0.50$).

Left ventricular apical rotation and LVEF represented the main correlates of LV torsion ($r = 0.93$, $r = 0.72$, respectively, $P < 0.001$ for both). The main correlates of LV apical rotation (analysed as a continuous variable) in patients with DCM were: LV systolic and diastolic volumes ($r = -0.36$, $P = 0.01$; $r = -0.37$, $P = 0.007$ respectively), LV sphericity index ($r = 0.34$, $P = 0.01$), LVFS ($r = 0.38$, $P = 0.006$), and QRS duration ($r = -0.48$, $P = 0.001$). A significant inverse correlation was found between QRS duration and LVEF in patients with DCM ($r = -0.33$, $P = 0.023$).

Intra-observer variability for measuring LV peak basal and peak apical rotation was 8.0 ± 6.7 and $6.6 \pm 5.8\%$, respectively. Inter-observer variability for the same parameters was 13 ± 7 and $11 \pm 8\%$, respectively. Of note, the agreement between the two observers with respect to the direction of apical rotation (+ or −) was 100%.

Discussion

The main findings of this study are: (i) in patients with DCM, severe LV dilation and increased sphericity are related to decreased or even reversed systolic apical rotation; (ii) reversed systolic apical rotation with consequent loss of LV torsion reflects a more advanced disease stage with more severe LV remodelling, LV

dyssynchrony, and more severe systolic and diastolic dysfunction compared to patients with DCM and normally directed apical rotation.

Left ventricular size and shape: relation with torsional behaviour

The geometry of the normal LV has been assimilated to a prolate ellipsoid with its long axis directed from apex to base. The LV myofibres geometry changes smoothly from a slightly oblique orientation in the subendocardium to a circumferential orientation in the mid-wall and again to an oblique orientation in the subepicardium.[13–15] The size and shape of the LV change in patients with DCM as the enlarged ventricle develops a spherical configuration. Thus, significant changes in LV rotational behaviour would be expected in this setting. Indeed, a decreased and delayed systolic torsion, depressed, delayed, and disorganized untwisting were previously reported in patients with DCM.[16]

Although reversed systolic apical rotation has recently been described in patients with DCM, the prevalence of such an abnormality, its determinants, and clinical implications have not been studied.[16–21] We found reversed apical rotation in a high percentage of patients with DCM (52%). A more severe LV remodelling was observed in these patients compared with those with normally directed apical rotation. Moreover, in patients with DCM, LV apical rotation was significantly related to LV diameters, volumes, and sphericity index. One may assume that such a pattern of apical rotation in patients with DCM and severely dilated ventricles could be explained by increased LV sphericity leading to widening of the apex. This results in the loss of the oblique architecture of the ascending and descending apical loop fibres which become more transverse and more closely resemble the horizontal fibre orientation of the basal loop.

In a recent paper van Dalen *et al.*[22] assessed LV twist characteristics in two small groups of patients with non-compaction cardiomyopathy (NCCM) and with DCM. A reversed systolic apical rotation with the loss of LV torsion was only observed in patients with NCCM. As a consequence, the authors proposed reversed apical rotation as a new diagnostic criterion for NCCM. It should be noted that in their study, LV diameters, volumes, and LVEF in patients with DCM were similar to those of our DCM (+) subgroup. Therefore, the lesser degree of LV remodelling in their patients could explain the lack of identification of reversed apical rotation in patients with DCM in that study.

Reversed apical rotation, assessed by tagging magnetic resonance imaging, was also found by Setser *et al.*[18] in 12/21 patients with DCM, a proportion similar to that found in our study. As LV end-diastolic volumes and LVEF were provided for each patient in that article, we calculated their mean values in patients with normally directed and with reversed apical rotation. End-diastolic volumes were significantly increased and LVEF was more severely reduced in patients with reversed apical rotation, supporting our findings.

More recently, Meluzin *et al.*[21] have also reported reversed apical rotation in 11/37 patients with idiopathic DCM.

Left ventricular function and rotational dynamics

Left ventricular torsion is a critically important mechanism for the efficiency of LV function. In our study, the amplitude of LV systolic rotation at both basal and apical levels and LV torsion were reduced in patients with DCM compared with normal subjects. There was also a significant correlation between LV torsion and degree of systolic dysfunction in patients with DCM, as previously reported.[17]

The importance of a normally functioning LV apex for normal cardiac performance is well known.[5,23,24] Left ventricular apical rotation represents the main determinant of global LV systolic torsion, while rapid apical back rotation plays an important role in the suction of blood into the LV, promoting its filling at low pressures.[4,5] Moreover, Kim *et al.*[25] demonstrated that in normal subjects LVEF correlated with apical, but not with basal rotation, whereas only basal rotation was age-related, suggesting the clinical relevance of apical rotation for assessing LV systolic performance even without the complex calculation of LV torsion.

Therefore, we presumed that LV systolic and diastolic performance would be more severely impaired in patients with reversed systolic apical rotation compared with those with normally directed apical rotation. We found significant differences in echocardiographic parameters of both systolic and diastolic function between the two groups. Left ventricular ejection fraction and LVFS were reduced, whereas LV filling pressures were increased in patients with reversed apical rotation.

A higher degree of MR in patients with reversed apical rotation and severe LV remodelling is not unexpected. It was recently shown that untwisting is delayed and slowed in patients with chronic severe primary MR and normal LVEF.[26] In our study, the difference in MR severity between the two DCM groups is most likely secondary to different degrees of LV remodelling. It is unlikely that MR degree by itself (only 1.8 ± 0.8 in the most severe group) had significantly influenced LV rotational patterns.

These results illustrate the intimate relationship between LV size, shape, and function: progressive LV dilation and increased sphericity lead to changes in myofibre orientation and in torsional dynamics. In turn, these changes lead to further deterioration of systolic and diastolic LV function.

QRS duration and left ventricular torsional behaviour

QRS duration is a significant predictor of LV systolic dysfunction in patients with heart failure. An inverse correlation exists between QRS duration and LVEF. Patients with heart failure and wide QRS complex have a higher all-cause mortality compared with those with narrow QRS complex.[27,28]

We also found a significant inverse correlation between QRS duration and LVEF in patients with DCM. Mean QRS duration was significantly higher in DCM (−) patients (*Table 3*) indicating a higher degree of electrical dyssynchrony. In patients with DCM, the amplitude of apical rotation was inversely related to QRS duration irrespective of the apical rotation pattern. Whether reversed apical rotation is only related to more severe LV structural remodelling or is partly due to higher electrical

dyssynchrony needs further study. The fact that there were patients with very wide QRS complex yet normally directed apical rotation and patients with normal QRS duration and reversed apical rotation suggests electrical dyssynchrony could not solely explain reversed apical rotation in this setting.

Measuring left ventricular rotation by speckle tracking echocardiography

Speckle tracking echocardiography is a feasible technique and allows new insights into the mechanisms of LV dysfunction in patients with DCM. The short-axis plane at the apex provides better acoustic conditions than at the base, and through-plane motion is minimal because of the limited longitudinal motion of the apex. Accordingly, speckle tracking at a distal apical short-axis plane is superior to what is achieved at the LV base.[4] In addition, the smaller size of the circular cut at the apex makes its recording easier in DCM, whereas the basal cut is sometimes difficult to include in a short-axis view in patients with very dilated ventricles.

Clinical implications

Our findings suggest that in patients with DCM, the progressive impairment of LV performance involves not only the increase in LV dimensions and sphericity, but also important changes in the pattern of LV rotation, most notably reversed apical rotation. It would be of interest to prospectively test whether patients with DCM and normally directed apical rotation develop reversed apical rotation during progression of LV remodelling.

The findings of our study highlight the importance of a normal apical rotation and preserved LV torsion for maintaining ventricular performance. This underscores the potential clinical benefits of therapeutic procedures such as cardiac resynchronization therapy (CRT) or apex-sparing volume reduction surgery in patients with DCM.[29]

Sade *et al.*[19] have recently described the effect of CRT on LV rotational mechanics. Of their 54 patients with DCM, seven had reversed apical rotation. This normalized in all of the responders after CRT except for one, who had ischaemic DCM with apical scar tissue. As we found reversed apical rotation in a significant proportion of our patients with DCM, this rotational parameter could be a useful marker to be assessed before and after CRT. Whether reversed apical rotation may help identify responders to CRT remains to be tested.

Study limitations

A larger sample size may be needed to demonstrate statistically significant clinical differences in terms of the NYHA class, a rather crude measure of functional capacity.

Although every effort was made to exclude coronary artery disease in our study group, this cannot be completely ruled out in the 20 patients in whom coronary angiography was not performed. However, studies reporting the effects of myocardial ischaemia on LV torsion described a reduction in LV apical rotation or even supranormal apical rotation with acute subendocardial ischaemia, but not reversed apical rotation. Therefore, we believe the association of reversed apical rotation with more severe LV remodelling found in our study holds true.

We recognize the technical limitations specific to the analysis of LV rotation and torsion by STE. However, the main finding of this study is based on an easy to assess rotational parameter (rotation direction: +/−), while measurement variability for peak apical and peak basal rotation was rather low in our study.

Conclusions

Reversed apical rotation and loss of LV torsion in patients with DCM is associated with significant LV remodelling, altered ventricular geometry, increased electrical dyssynchrony, reduced systolic function, and increased LV filling pressures. These findings identify a subgroup of patients with more advanced disease.

Acknowledgements

We thank Dr Cosmin Călin for his assistance with the drawings used in *Figure 1*. We gratefully acknowledge the support of our colleagues who have referred patients for this study.

Funding

This work was supported by a Romanian National Research Programme II grant, [grant number ID_222, contract 199/2007], IDEI 2007.

Conflict of interest: None declared.

References

1. Sengupta PP, Korinek J, Belohlavek M, Narula J, Vannan MA, Jahangir A, Khandheria BK. Left ventricular structure and function: basic science for cardiac imaging. *J Am Coll Cardiol* 2006;**48**:1988–2001.
2. Taber LA, Yang M, Podszus WW. Mechanics of ventricular torsion. *J Biomech* 1996;**29**:745–752.
3. Sengupta PP, Tajik JA, Chandrasekaran K, Khandheria BK. Twist mechanics of the left ventricle: principles and application. *J Am Coll Cardiol Img* 2008;**1**:366–376.
4. Opdahl A, Helle-Valle T, Remme EW, Vartdal T, Pettersen E, Lunde K, Edvardsen T, Smiseth OA. Apical rotation by speckle tracking echocardiography: a simplified bedside index of left ventricular twist. *J Am Soc Echocardiogr* 2008;**21**: 1121–1128.
5. Notomi Y, Martin-Miklovic MG, Oryszak SJ, Shiota T, Deserranno D, Popovic ZB, Garcia MJ, Greenberg NL, Thomas JD. Enhanced ventricular untwisting during exercise: a mechanistic manifestation of elastic recoil described by Doppler tissue imaging. *Circulation* 2006;**113**:2524–2533.
6. Helle-Valle T, Crosby J, Edvardsen T, Lyseggen E, Amundsen BH, Smith HJ, Rosen BD, Lima JA, Torp H, Ihlen H, Smiseth OA. New noninvasive method for assessment of left ventricular rotation: speckle tracking echocardiography. *Circulation* 2005;**112**:3149–3156.
7. Notomi Y, Lysyansky P, Setser RM, Shiota T, Popovic ZB, Martin-Miklovic MG, Weaver JA, Oryszak SJ, Greenberg NL, White RD, Thomas JD. Measurement of ventricular torsion by two-dimensional ultrasound speckle tracking imaging. *J Am Coll Cardiol* 2005;**45**:2034–2041.
8. Lang RM, Bierig M, Devereux RB, Flachskampf FA, Foster E, Pellikka PA, Picard MH, Roman MJ, Seward J, Shanewise JS, Solomon SD, Spencer KT, Stewart WJ. Recommendations for Chamber Quantification: A Report from the American Society of Echocardiography's Guidelines and Standards Committee and the Chamber Quantification Writing Group, Developed in Conjunction with the European Association of Echocardiography, a Branch of the European Society of Cardiology. *J Am Soc Echocardiogr* 2005;**18**:1440–1463.
9. Devereux RB, Alonso DR, Lutas EM, Gottlieb GJ, Campo E, Sachs I, Reichek N. Echocardiographic assessment of left ventricular hypertrophy: comparison to necropsy findings. *Am J Cardiol* 1986;**57**:450–458.
10. Ommen SR, Nishimura RA, Appleton CP, Miller FA, Oh JK, Redfield MM, Tajik AJ. Clinical utility of Doppler echocardiography and tissue Doppler imaging in the estimation of left ventricular filling pressures: a comparative simultaneous Doppler-catheterization study. *Circulation* 2000;**102**:1788–1794.
11. Zoghbi WA, Enriquez-Sarano M, Foster E, Grayburn PA, Kraft CD, Levine RA, nihoyannopoulos P, Otto CM, Quiniones NA, Rakowski H, Stewart WJ, Waggonner A, Weisman N, American Society of Echocardiography. Recommendations for evaluation of the severity of native valvular regurgitation with two-

dimensional and Doppler echocardiography. *J Am Soc Echocardiogr* 2003;**16**: 777–802.
12. van Dalen BM, Vletter WB, Soliman OI, ten Cate FJ, Geleijnse ML. Importance of transducer position in the assessment of apical rotation by speckle tracking echocardiography. *J Am Soc Echocardiogr* 2008;**21**:895–898.
13. Streeter DD Jr, Spotnitz HM, Patel DP, Ross J Jr, Sonnenblick EH. Fiber orientation in the canine left ventricle during diastole and systole. *Circ Res* 1969;**24**: 339–347.
14. Greenbaum RA, Ho SY, Gibson DG, Becker AE, Anderson RH. Left ventricular fibre architecture in man. *Br Heart J* 1981;**45**:248–263.
15. Ingels NB Jr, Hansen DE, Daughters GT 2nd, Stinson EB, Alderman EL, Miller DC. Relation between longitudinal, circumferential, and oblique shortening and torsional deformation in the left ventricle of the transplanted human heart. *Circ Res* 1989;**64**:915–927.
16. Kanzaki H, Nakatani S, Yamada N, Urayama Si, Miyatake K, Kitakaze M. Impaired systolic torsion in dilated cardiomyopathy: reversal of apical rotation at mid-systole characterized with magnetic resonance tagging method. *Basic Res Cardiol* 2006;**101**:465–470.
17. Jin SM, Noh CI, Bae EJ, Choi JY, Yun YS. Decreased left ventricular torsion and untwisting in children with dilated cardiomyopathy. *J Korean Med Sci* 2007;**22**: 633–640.
18. Setser RM, Smedira NG, Lieber ML, Starling RC, McCarthy PM, White RD. Left ventricular torsional mechanics after left ventricular reconstruction surgery for ischemic cardiomyopathy. *J Thorac Cardiovasc Surg* 2007;**134**:888–896.
19. Sade LE, Demir O, Atar I, Müderrisogl H, Özin B. Effect of mechanical dyssynchrony and cardiac resynchronization therapy on left ventricular rotational mechanics. *Am J Cardiol* 2008;**101**:1163–1169.
20. Saito M, Okayama H, Nishimura K, Ogimoto A, Ohtsuka T, Inoue K, Hiasa G, Sumimoto T, Funada J, Shigematsu Y, Higaki J. Determinants of left ventricular untwisting behaviour in patients with dilated cardiomyopathy: analysis by two-dimensional speckle tracking. *Heart* 2009;**95**:290–296.
21. Meluzin J, Spinarova L, Hude P, Krejci J, Poloczkova H, Podrouzkova H, Pesl M, Orban M, Dusek L, Korinek J. Left ventricular mechanics in idiopathic dilated cardiomyopathy: systolic-diastolic coupling and torsion. *J Am Soc Echocardiogr* 2009; **22**:486–493.
22. van Dalen BM, Caliskan K, Soliman OI, Nemes A, Vletter WB, ten Cate FJ, Geleijnse ML. Left ventricular solid body rotation in non-compaction cardiomyopathy: a potential new objective and quantitative functional diagnostic criterion? *Eur J Heart Fail* 2008;**10**:1088–1093.
23. Hori M, Yeliin EL, Sonnenblick EH. Left ventricular diastolic suction as a mechanism of ventricular filling. *Jpn Circ J* 1982;**46**:124–129.
24. Suga H, Goto Y, Igarashi Y, Yamada O, Nozawa T, Yasumura Y. Ventricular suction under zero source pressure for filling. *Am J Physiol Heart Circ Physiol* 1986;**251**:H47–H55.
25. Kim HK, Sohn DW, Lee SE, Choi SY, Park JS, Kim YJ, Oh BH, Park YB, Choi YS. Assessment of left ventricular rotation and torsion with two-dimensional speckle tracking echocardiography. *J Am Soc Echocardiogr* 2007;**20**:45–53.
26. Borg AN, Harrison JL, Argyle RA, Ray SG. Left ventricular torsion in primary chronic mitral regurgitation. *Heart* 2008;**94**:597–603.
27. Kashani A, Barold SS. Significance of QRS complex duration in patients with heart failure. *J Am Coll Cardiol* 2005;**46**:2183–2192.
28. Sandhu R, Bahler RC. Prevalence of QRS prolongation in a community hospital cohort of patients with heart failure and its relation to left ventricular systolic dysfunction. *Am J Cardiol* 2004;**93**:244–246.
29. Koyama T, Nishimura K, Soga S, Unimonh O, Ueyama K, Komeda M. Importance of preserving the apex and plication of the base in left ventricular volume reduction surgery. *J Thorac Cardiovasc Surg* 2003;**125**:669–677.